

## Toufic Chaaban

Ohio State University Wexner Medical Center, Columbus, United States

# Acute eosinophilic pneumonia associated with non-cigarette smoking products: a systematic review

## Abstract

Acute eosinophilic pneumonia (AEP) is characterized by an acute onset respiratory illness with bilateral chest infiltrates and evidence of pulmonary eosinophilia. Cigarette smoking is the main risk factor, but drugs and other inhalational exposures have also been reported. Herein, the association between AEP and smoking devices other than cigarettes is reviewed

The PubMed database was searched using terms such as “smoking”, “vaping”, “e-cigarette”, “waterpipe”, and “marijuana”, along with other commonly used synonyms for these terms. In addition, eosinophilic lung diseases were also searched for using the same database. All cases of AEP were identified using the modified Pilit criteria in association with the use of marijuana, waterpipe, e-cigarettes or heat-not-burn cigarettes. Cases associated with illicit drug use were excluded.

Twelve cases were included with a median age of 20 (15–60). 75% of patients studied were male. Exposures included marijuana smoking (n = 5), waterpipe usage (n = 2), heat-not-burn cigarette use (n = 2), e-cigarette use (n = 2) and synthetic cannabinoid use (n = 1). A recent change in smoking habits was reported in 50% of patients. Presenting symptoms were dyspnea (91.6%), cough (66.6%), fever (66.6%) and chest pain (25%). 90% of patients had leukocytosis on presentation, but only 16.6% had peripheral eosinophilia. The median eosinophil percentage in bronchoalveolar lavage was 67.5% (0 to 78). Two patients had a lung biopsy performed. Bilateral involvement on chest imaging was reported in all patients. Five patients (41.6%) required invasive mechanical ventilation and ten patients (83.3%) were treated in an intensive care unit. All patients responded to corticosteroid therapy with no relapses reported.

Acute eosinophilic pneumonia is reported with smoking that does not include traditional cigarette smoking such as waterpipes, e-cigarettes, heat-not-burn cigarettes, and marijuana and can have a similar presentation and clinical course.

**Key words:** eosinophilic pneumonia, smoking, e-cigarette, waterpipe, vaping, marijuana, cannabis

**Adv Respir Med. 2020; 88: 142–146**

## Introduction

Acute eosinophilic pneumonia (AEP) is an eosinophilic lung disease characterized by an acute onset febrile respiratory illness with bronchoalveolar lavage eosinophilia that promptly responds to treatment with steroids. While the disease can be idiopathic, cigarette smoking is a major risk factor [1, 2] and commonly occurs in the setting of new exposure or a recent change in smoking habits [3, 4]. Drug use and other inhalational exposures are also known triggers [5–7]. Here, the reported cases of AEP in association with non-cigarette smoking such as e-cigarette, marijuana, and waterpipe smoking are reviewed.

## Material and methods

The PubMed database was searched using the following keywords: smoking, electronic nicotine delivery systems, waterpipe, hookah, shisha, marijuana, cannabis, non-cigarette tobacco, vaping, e-cigarettes, electronic cigarettes and cannabis sativa. These keywords were searched for in combination with the following medical complications: eosinophilic pneumonia, respiratory distress syndrome, ARDS, respiratory insufficiency, and pulmonary eosinophilia. The “Related articles” section in PubMed was used to screen for additional relevant articles. The reference lists of the relevant articles were also screened to look

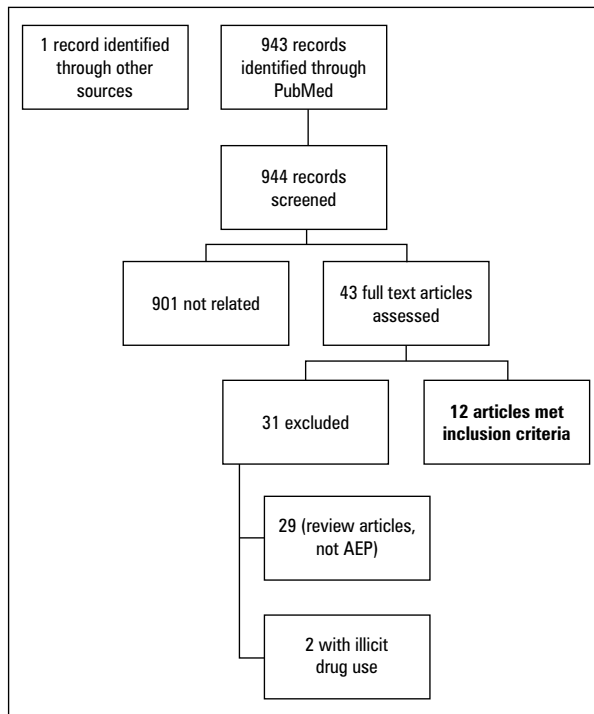
**Address for correspondence:** Toufic Chaaban, Ohio State University Wexner Medical Center, Columbus, United States; e-mail: t-chaaban@hotmail.com

DOI: 10.5603/ARM.2020.0088

Received: 15.01.2020

Copyright © 2020 PTChP

ISSN 2451–4934



**Figure 1.** Study flowchart  
AEP — acute eosinophilic pneumonia

for other manuscripts eligible for the current review. Cases were included if they involved cases of AEP defined as: 1) Acute respiratory illness of 1-month duration or less; 2) Bilateral pulmonary infiltrates on chest imaging; 3) Eosinophilic pneumonia detected by Bronchoalveolar lavage (BAL) with eosinophils totaling more than 25% or showing eosinophilic pneumonia on lung biopsy. In addition, exposure to smoking items other than traditional cigarettes was required and included cannabis, electronic cigarettes, heat-not-burn cigarettes, waterpipes and hookahs. Cases with exposure to illicit drug use were excluded. The results of this search are summarized in Figure 1. 943 abstracts were reviewed and 42 of them were identified for full text review (in addition to one relevant report identified by screening the references of the reviewed articles). Two were excluded because of illicit drug use exposure and 29 articles were not relevant (review articles or no relevant exposure). Twelve cases met the inclusion criteria (Figure 1).

## Results

### Patient characteristics and exposures

Table 1 summarizes the reported cases and patient demographics. 12 cases of AEP linked to non-cigarette smoking were reported with the

patients having a median age of 20 (range 15–60). 42.6% were younger or equal to 18 years of age and 75% were male. Exposures reported included patients who smoked marijuana (n = 5), used a waterpipe (n = 2), smoked heat-not-burn cigarettes (n = 2), used e-cigarettes (n = 2), and one who used synthetic cannabinoids (n = 1). 25% reported associated cigarette smoking. A recent change in smoking habits was reported in 50% of patients and included the following: new initiation within 1 month in one patient, recent product change in four patients, and restarting less than 1 month in 3 patients. One patient also reported starting cigarette smoking within 1 month of symptom onset. Time from the last inhalational exposure to onset of symptoms was reported in 5 cases; three of them occurred within 1 day, one occurred after 2 days, and one occurred after 2 weeks. Two patients reported comorbid asthma.

### Clinical manifestations, laboratory and radiological findings

Patients presented with dyspnea (91.6%), cough (66.6%), fever (66.6%) and chest pain (25%). Lung auscultation findings were reported in 9 out of 12 patients and findings included crackles (55.5%) and wheezing (22.2%). White blood cell count (WBCs) was reported in 11 patients with a median of  $19.95 \times 10^9/L$  (range 5.8 to 28) with 90% having leukocytosis as defined by WBC count greater than  $11 \times 10^9$  cells/L. Only 2 patients (16.6) had peripheral eosinophilia on presentation. Three additional patients (25%) developed peripheral eosinophilia during their hospitalization.

Bronchoalveolar lavage eosinophil cell count was reported in 11 out of 12 patients. In one of the patients, the procedure had to be aborted due to hypoxemia which resulted in an inadequate sample. Of the remaining ten patients, the median eosinophil percentage was 67.5% (range 0 to 78) with 90% of patients having an eosinophil count totaling more than 25%. The only patient who had less than 25% (0 eosinophils) was treated with corticosteroids prior to bronchoscopy. One patient's sputum was sent for evaluation and their eosinophil count was 14%. IgE levels were reported in 4 patients; they were normal in three patients and elevated in one. Lung biopsies were obtained in two patients and confirmed eosinophilic pneumonia. One of these biopsies was conducted using video assisted thoracoscopic surgery (VATS), while the other sampling method was not specified.

Bilateral involvement on chest imaging was reported in all patients. Computed tomography

**Table 1. Articles reviewed and patient characteristics**

Publication	Exposure	Study design	Number of patients with AEP	Age	Gender	Current cigarette smoker
Sauvaget <i>et al.</i> 2010 [8]	Marijuana	Case report	1	15	M	Yes
Liebling <i>et al.</i> 2013 [9]	Marijuana	Case report	1	60	M	No
Natarajan <i>et al.</i> 2013 [10]	Marijuana	Case report	1	29	M	Yes
Dyal <i>et al.</i> 2014 [11]	Hookah	Case report	1	26	F	No
Thota <i>et al.</i> 2014 [12]	E-cigarette	Case report	1	20	M	No
Kang <i>et al.</i> 2016 [13]	Hookah	Case report	1	NA	M	No
Kamada <i>et al.</i> 2016 [14]	Heat not burn	Case report	1	20	M	No
Schlossma <i>et al.</i> 2017 [15]	Synthetic cannabinoids inhaled	Case report/ /poster presentation	1	18	F	No
McElligott <i>et al.</i> 2017 [16]	Marijuana	Case report/ /poster presentation	1	20	M	Yes
McGraw <i>et al.</i> 2018 [17]	Marijuana	Case series	1	17	M	No
Aokage <i>et al.</i> 2019 [18]	Heat not burn	Case report	1	16	M	No
Arter <i>et al.</i> 2019 [19]	E-cigarette	Case report	1	18	F	No

AEP — acute eosinophilic pneumonia

**Table 2. Computed tomography (CT) of the chest findings**

CT chest findings	N (%)
Ground glass opacities	7 (58)
Consolidation/infiltrates	6 (50)
Nodules/nodular infiltrates	2 (16.6)
Interlobular septal thickening	3 (25)
Tree in bud	1 (8.3)
Pleural effusions	4 (33.3)

of the chest (CT chest) findings are summarized in Table 2.

**Treatment and outcomes**

Two patients (16.6%) did not require respiratory support, two patients (16.6%) required supplemental oxygen therapy, 1 patient (8.3%) was treated with noninvasive positive pressure ventilation, and 5 patients (41.6%) required invasive mechanical ventilation. One patient required extracorporeal membrane oxygenation (ECMO) and another patient was transferred for ECMO to another institution. Ten patients (83.3%) were treated in an intensive care unit. All patients received corticosteroids with varying regimens with five of them (41.6%) receiving oral corticosteroids. All patients responded to steroid therapy with no relapses reported.

**Discussion**

Acute eosinophilic pneumonia is a disease characterized by an acute respiratory illness with bilateral involvement on chest imaging, pulmonary eosinophilia and a prompt response to treatment with corticosteroids. It commonly progresses to respiratory failure requiring invasive mechanical ventilation and intensive care [1, 4, 20]. Philit *et al.* [21] suggested diagnostic criteria which required subsequent modifications [1, 4] seeing as hypoxemia is not present in all patients and recovery without steroids was reported. Cigarette smoking is a strong risk factor [1, 2] and patients frequently report recent initiation of smoking, a change in smoking habits [3, 4], drug use and/or other inhalational exposures [5, 6, 22, 23]. Non-cigarette forms of smoking are increasingly used. These include e-cigarettes [24, 25], waterpipe/hookah smoking [25–27], and marijuana use [28]. Younger populations are mainly at risk and include adolescents as well as college and university students [26, 29–31]. Recently, an outbreak of vaping induced lung injury was reported [32]. Other pulmonary effects of vaping include: bronchial toxicity [33], lipid pneumonia [34], diffuse alveolar hemorrhage [35], hypersensitivity pneumonitis [36], and organizing pneumonia [37]. In the current review, literature was researched for reported cases of AEP associated with these exposures. The median age in the

reviewed cases was 20 with 42% being 18 years of age or younger. This reflects the increasing use of such products by the young and adolescent population, and the need for public health policies and awareness to address this problem as they are frequently falsely perceived as safe by the public. In addition to the direct health consequences of these products, they increase the risk of traditional cigarette smoking in users [38]. As reported by Rhee *et al.* [4], the exposure to other types of smoking was frequently recently started or altered (50% of patients) similarly to traditional cigarette smokers. Fever was present in 66.6% of the patients, but higher percentages were reported in other studies (mean 80%) [1]. Peripheral eosinophilia was not common during presentation and this is a related finding to Giacomini *et al.* [5] who reported a lower incidence of peripheral eosinophilia in smoking associated AEP (36%) compared to other causes. Cigarette smoking and other types of smoking likely share common pathophysiological mechanisms which might explain why peripheral eosinophilia was uncommon upon presentation in this review similarly to smoking associated AEP. Like in other studies [1, 20], peripheral eosinophilia can arise during hospitalization (25% in the reviewed cases above). Bronchoalveolar lavage eosinophilia was present in most of the reviewed cases. One patient had no eosinophils on BAL, but the diagnosis of eosinophilic pneumonia was later confirmed by biopsy. In this patient, the BAL was done after corticosteroid therapy. In another patient, the procedure had to be aborted due to hypoxemia. The retrieved sample had an eosinophil count of 6% and biopsy obtained by VATS confirmed eosinophilic pneumonia but the sample was deemed ineligible due to the aforementioned complication during the procedure. One patient had sputum cytology showing eosinophilia without a reported BAL and responded promptly to corticosteroid therapy. Like other studies [1, 4], ground glass opacities (GGO) and bilateral infiltrates were the most common chest imaging findings. Pleural effusions were less common in the reviewed cases. Some radiological details might have been missed from the case reports. Invasive mechanical ventilation was required in 41.6% of patients. One patient required ECMO. Rates of mechanical ventilation are lower in AEP studies (mean 25%) [1]. This review included only case reports where there was a possibility of reporting bias where severe cases are reported more than milder ones. Different corticosteroid regimens were used with an excellent response

in all patients. The regimens used varied and no conclusions can be drawn from these cases, but prior data in AEP associated with other causes showed that treatment duration could potentially be shortened to 2 weeks [4]. This review is limited by the quality of data available that comes mainly from case reports. Clinical, radiological and laboratory details might have been omitted. Also, reporting bias cannot be excluded as the exposure is sometimes not disclosed by patients.

## Conclusion

AEP is reported with smoking outside of traditional cigarette smoking including vaping, waterpipe smoking, marijuana and HNBCs. The disease has a similar presentation and clinical course to AEP associated with cigarette smoking and other exposures.

## Conflict of interest

None declared

## References:

1. Sine CR, Hiles PD, Scoville SL, et al. Acute eosinophilic pneumonia in the deployed military setting. *Respir Med.* 2018; 137: 123–128, doi: [10.1016/j.rmed.2018.03.004](https://doi.org/10.1016/j.rmed.2018.03.004), indexed in Pubmed: [29605194](https://pubmed.ncbi.nlm.nih.gov/29605194/).
2. Yoon Cg, Kim SeJ, Kim K, et al. Clinical characteristics and factors influencing the occurrence of acute eosinophilic pneumonia in Korean military personnel. *J Korean Med Sci.* 2016; 31(2): 247–253, doi: [10.3346/jkms.2016.31.2.247](https://doi.org/10.3346/jkms.2016.31.2.247), indexed in Pubmed: [26839479](https://pubmed.ncbi.nlm.nih.gov/26839479/).
3. Uchiyama H, Suda T, Nakamura Y, et al. Alterations in smoking habits are associated with acute eosinophilic pneumonia. *Chest.* 2008; 133(5): 1174–1180, doi: [10.1378/chest.07-2669](https://doi.org/10.1378/chest.07-2669), indexed in Pubmed: [18263675](https://pubmed.ncbi.nlm.nih.gov/18263675/).
4. Rhee CK, Min KH, Yim NY, et al. Clinical characteristics and corticosteroid treatment of acute eosinophilic pneumonia. *Eur Respir J.* 2013; 41(2): 402–409, doi: [10.1183/09031936.00221811](https://doi.org/10.1183/09031936.00221811), indexed in Pubmed: [22599359](https://pubmed.ncbi.nlm.nih.gov/22599359/).
5. De Giacomini F, Decker PA, Vassallo R, et al. Acute eosinophilic pneumonia: correlation of clinical characteristics with underlying cause. *Chest.* 2017; 152(2): 379–385, doi: [10.1016/j.chest.2017.03.001](https://doi.org/10.1016/j.chest.2017.03.001), indexed in Pubmed: [28286263](https://pubmed.ncbi.nlm.nih.gov/28286263/).
6. De Giacomini F, Vassallo R, Yi ES, et al. Acute eosinophilic pneumonia. Causes, diagnosis, and management. *Am J Respir Crit Care Med.* 2018; 197(6): 728–736, doi: [10.1164/rccm.201710-1967CI](https://doi.org/10.1164/rccm.201710-1967CI), indexed in Pubmed: [29206477](https://pubmed.ncbi.nlm.nih.gov/29206477/).
7. Wilson KC, Saukkonen JJ. Acute respiratory failure from abused substances. *J Intensive Care Med.* 2004; 19(4): 183–193, doi: [10.1177/0885066604263918](https://doi.org/10.1177/0885066604263918), indexed in Pubmed: [15296619](https://pubmed.ncbi.nlm.nih.gov/15296619/).
8. Sauvaget E, Dellamonica J, Arlaud K, et al. Idiopathic acute eosinophilic pneumonia requiring ECMO in a teenager smoking tobacco and cannabis. *Pediatr Pulmonol.* 2010; 45(12): 1246–1249, doi: [10.1002/ppul.21314](https://doi.org/10.1002/ppul.21314), indexed in Pubmed: [20812251](https://pubmed.ncbi.nlm.nih.gov/20812251/).
9. Liebling PD, Siu S. A novel cause of eosinophilic pneumonia: recreational marijuana exposure. *J Bronchology Interv Pulmonol.* 2013; 20(2): 183–185, doi: [10.1097/LBR.0b013e31828ca0d](https://doi.org/10.1097/LBR.0b013e31828ca0d), indexed in Pubmed: [23609259](https://pubmed.ncbi.nlm.nih.gov/23609259/).
10. Natarajan A, Shah P, Mirrakhimov AE, et al. Eosinophilic pneumonia associated with concomitant cigarette and mari-

- juana smoking. *BMJ Case Rep.* 2013; 2013, doi: [10.1136/bcr-2013-009001](https://doi.org/10.1136/bcr-2013-009001), indexed in Pubmed: [23645642](https://pubmed.ncbi.nlm.nih.gov/23645642/).
11. Dyal H, Singhvi A, Patel R, et al. A case of eosinophilic pneumonia following recent onset of hookah smoking. *Chest.* 2014; 146(4), doi: [10.1378/chest.1968687](https://doi.org/10.1378/chest.1968687).
  12. Thota D, Latham E. Case report of electronic cigarettes possibly associated with eosinophilic pneumonitis in a previously healthy active-duty sailor. *J Emerg Med.* 2014; 47(1): 15–17, doi: [10.1016/j.jemermed.2013.09.034](https://doi.org/10.1016/j.jemermed.2013.09.034), indexed in Pubmed: [24462024](https://pubmed.ncbi.nlm.nih.gov/24462024/).
  13. Kang M, Raj V, Berman AR. A man in his 20s with diffuse lung opacities and acute respiratory failure after hookah smoking. *Chest.* 2016; 150(6): e175–e178, doi: [10.1016/j.chest.2016.10.009](https://doi.org/10.1016/j.chest.2016.10.009), indexed in Pubmed: [27938776](https://pubmed.ncbi.nlm.nih.gov/27938776/).
  14. Kamada T, Yamashita Y, Tomioka H. Acute eosinophilic pneumonia following heat-not-burn cigarette smoking. *Respir Case Rep.* 2016; 4(6): e00190, doi: [10.1002/rcr2.190](https://doi.org/10.1002/rcr2.190), indexed in Pubmed: [28031826](https://pubmed.ncbi.nlm.nih.gov/28031826/).
  15. Schlossman T, Sangani R, Hussain K. Acute eosinophilic pneumonia from exposure to synthetic cannabinoids. *Chest.* 2017; 152(4): A425, doi: [10.1016/j.chest.2017.08.452](https://doi.org/10.1016/j.chest.2017.08.452).
  16. McElligott M, Carrington J, Huebert C. Acute eosinophilic pneumonia following marijuana inhalation. *Chest.* 2017; 152(4): A426, doi: [10.1016/j.chest.2017.08.453](https://doi.org/10.1016/j.chest.2017.08.453).
  17. McGraw MD, Houser GH, Galambos C, et al. Marijuana medusa: The many pulmonary faces of marijuana inhalation in adolescent males. *Pediatr Pulmonol.* 2018; 53(12): 1619–1626, doi: [10.1002/ppul.24171](https://doi.org/10.1002/ppul.24171), indexed in Pubmed: [30353708](https://pubmed.ncbi.nlm.nih.gov/30353708/).
  18. Aokage T, Tsukahara K, Fukuda Y, et al. Heat-not-burn cigarettes induce fulminant acute eosinophilic pneumonia requiring extracorporeal membrane oxygenation. *Respir Med Case Rep.* 2019; 26: 87–90, doi: [10.1016/j.rmcr.2018.12.002](https://doi.org/10.1016/j.rmcr.2018.12.002), indexed in Pubmed: [30560050](https://pubmed.ncbi.nlm.nih.gov/30560050/).
  19. Arter ZL, Wiggins A, Hudspath C, et al. Acute eosinophilic pneumonia following electronic cigarette use. *Respir Med Case Rep.* 2019; 27: 100825, doi: [10.1016/j.rmcr.2019.100825](https://doi.org/10.1016/j.rmcr.2019.100825), indexed in Pubmed: [30963023](https://pubmed.ncbi.nlm.nih.gov/30963023/).
  20. Cottin V. Eosinophilic lung diseases. *Clin Chest Med.* 2016; 37(3): 535–556, doi: [10.1016/j.ccm.2016.04.015](https://doi.org/10.1016/j.ccm.2016.04.015), indexed in Pubmed: [27514599](https://pubmed.ncbi.nlm.nih.gov/27514599/).
  21. Philit F, Etienne-Mastroianni B, Parrot A, et al. Idiopathic acute eosinophilic pneumonia: a study of 22 patients. *Am J Respir Crit Care Med.* 2002; 166(9): 1235–1239, doi: [10.1164/rccm.2112056](https://doi.org/10.1164/rccm.2112056), indexed in Pubmed: [12403693](https://pubmed.ncbi.nlm.nih.gov/12403693/).
  22. Lin SS, Chen YC, Chang YL, et al. Crystal amphetamine smoking-induced acute eosinophilic pneumonia and diffuse alveolar damage: a case report and literature review. *Chin J Physiol.* 2014; 57(5): 295–298, doi: [10.4077/CJP.2014.BAC201](https://doi.org/10.4077/CJP.2014.BAC201), indexed in Pubmed: [25241990](https://pubmed.ncbi.nlm.nih.gov/25241990/).
  23. Al-Saieg N, Moammar O, Kartan R. Flavored cigar smoking induces acute eosinophilic pneumonia. *Chest.* 2007; 131(4): 1234–1237, doi: [10.1378/chest.06-2623](https://doi.org/10.1378/chest.06-2623), indexed in Pubmed: [17426233](https://pubmed.ncbi.nlm.nih.gov/17426233/).
  24. McMillen RC, Gottlieb MA, Shaefer RM, et al. Trends in electronic cigarette use among U.S. Adults: use is increasing in both smokers and nonsmokers. *Nicotine Tob Res.* 2015; 17(10): 1195–1202, doi: [10.1093/ntr/ntu213](https://doi.org/10.1093/ntr/ntu213), indexed in Pubmed: [25381306](https://pubmed.ncbi.nlm.nih.gov/25381306/).
  25. Owens VL, Ha T, Soulakova JN. Widespread use of flavored e-cigarettes and hookah tobacco in the United States. *Prev Med Rep.* 2019; 14: 100854, doi: [10.1016/j.pmedr.2019.100854](https://doi.org/10.1016/j.pmedr.2019.100854), indexed in Pubmed: [30976489](https://pubmed.ncbi.nlm.nih.gov/30976489/).
  26. Sutfin EL, McCoy TP, Reboussin BA, et al. Prevalence and correlates of waterpipe tobacco smoking by college students in North Carolina. *Drug Alcohol Depend.* 2011; 115(1-2): 131–136, doi: [10.1016/j.drugalcdep.2011.01.018](https://doi.org/10.1016/j.drugalcdep.2011.01.018), indexed in Pubmed: [21353750](https://pubmed.ncbi.nlm.nih.gov/21353750/).
  27. Jawad M, Charide R, Waziry R, et al. The prevalence and trends of waterpipe tobacco smoking: A systematic review. *PLoS One.* 2018; 13(2): e0192191, doi: [10.1371/journal.pone.0192191](https://doi.org/10.1371/journal.pone.0192191), indexed in Pubmed: [29425207](https://pubmed.ncbi.nlm.nih.gov/29425207/).
  28. Hasin DS, Saha TD, Kerridge BT, et al. Prevalence of marijuana use disorders in the united states between 2001–2002 and 2012–2013. *JAMA Psychiatry.* 2015; 72(12): 1235–1242, doi: [10.1001/jamapsychiatry.2015.1858](https://doi.org/10.1001/jamapsychiatry.2015.1858), indexed in Pubmed: [26502112](https://pubmed.ncbi.nlm.nih.gov/26502112/).
  29. Demissie Z, Everett Jones S, Clayton HB, et al. Adolescent risk behaviors and use of electronic vapor products and cigarettes. *Pediatrics.* 2017; 139(2), doi: [10.1542/peds.2016-2921](https://doi.org/10.1542/peds.2016-2921), indexed in Pubmed: [28115539](https://pubmed.ncbi.nlm.nih.gov/28115539/).
  30. Ramo DE, Young-Wolff KC, Prochaska JJ. Prevalence and correlates of electronic-cigarette use in young adults: findings from three studies over five years. *Addict Behav.* 2015; 41: 142–147, doi: [10.1016/j.addbeh.2014.10.019](https://doi.org/10.1016/j.addbeh.2014.10.019), indexed in Pubmed: [25452058](https://pubmed.ncbi.nlm.nih.gov/25452058/).
  31. Primack BA, Shensa A, Kim KH, et al. Waterpipe smoking among U.S. university students. *Nicotine Tob Res.* 2013; 15(1): 29–35, doi: [10.1093/ntr/nts076](https://doi.org/10.1093/ntr/nts076), indexed in Pubmed: [22641433](https://pubmed.ncbi.nlm.nih.gov/22641433/).
  32. Layden JE, Ghinai I, Pray I, et al. Pulmonary illness related to e-cigarette use in Illinois and Wisconsin — final report. *N Engl J Med.* 2020; 382(10): 903–916, doi: [10.1056/NEJMoa1911614](https://doi.org/10.1056/NEJMoa1911614), indexed in Pubmed: [31491072](https://pubmed.ncbi.nlm.nih.gov/31491072/).
  33. Hureaux J, Drouet M, Urban T. A case report of subacute bronchial toxicity induced by an electronic cigarette. *Thorax.* 2014; 69(6): 596–597, doi: [10.1136/thoraxjnl-2013-204767](https://doi.org/10.1136/thoraxjnl-2013-204767), indexed in Pubmed: [24436327](https://pubmed.ncbi.nlm.nih.gov/24436327/).
  34. Viswam D, Trotter S, Burge PS, et al. Respiratory failure caused by lipoid pneumonia from vaping e-cigarettes. *BMJ Case Rep.* 2018; 2018, doi: [10.1136/bcr-2018-224350](https://doi.org/10.1136/bcr-2018-224350), indexed in Pubmed: [29982176](https://pubmed.ncbi.nlm.nih.gov/29982176/).
  35. Agustin M, Yamamoto M, Cabrera F, et al. Diffuse alveolar hemorrhage induced by vaping. *Case Rep Pulmonol.* 2018; 2018: 9724530, doi: [10.1155/2018/9724530](https://doi.org/10.1155/2018/9724530), indexed in Pubmed: [29984031](https://pubmed.ncbi.nlm.nih.gov/29984031/).
  36. Sommerfeld CG, Weiner DJ, Nowalk A, et al. Hypersensitivity pneumonitis and acute respiratory distress syndrome from e-cigarette use. *Pediatrics.* 2018; 141(6), doi: [10.1542/peds.2016-3927](https://doi.org/10.1542/peds.2016-3927), indexed in Pubmed: [29773665](https://pubmed.ncbi.nlm.nih.gov/29773665/).
  37. Khan MS, Khateeb F, Akhtar J, et al. Organizing pneumonia related to electronic cigarette use: A case report and review of literature. *Clin Respir J.* 2018; 12(3): 1295–1299, doi: [10.1111/crj.12775](https://doi.org/10.1111/crj.12775), indexed in Pubmed: [29392888](https://pubmed.ncbi.nlm.nih.gov/29392888/).
  38. Treur JL, Rozema AD, Mathijssen JJP, et al. E-cigarette and waterpipe use in two adolescent cohorts: cross-sectional and longitudinal associations with conventional cigarette smoking. *Eur J Epidemiol.* 2018; 33(3): 323–334, doi: [10.1007/s10654-017-0345-9](https://doi.org/10.1007/s10654-017-0345-9), indexed in Pubmed: [29260431](https://pubmed.ncbi.nlm.nih.gov/29260431/).